



## PATIENT

Mia Caban

## SPECIES

Canine

## BREED

Mixed

## SEX

FS

## AGE

8 y

## WEIGHT

14.6 lb

## INTERPRETED BY

Keith Blass, DVM, MS,  
DACVIM (Cardiology)

## IMAGING PERFORMED BY

Gabriel Ferrer, DVM

## HOSPITAL NAME

Pulse Pet Ultrasound  
Services

## REFERRING VET

Dr. Trappler

## INVOICE

## DATE

3/18/26

## PRESENTING CLINICAL SIGNS

Pre-anesthetic evaluation (pulmonary carcinoma excision). Originally visited ER due to increased respiratory effort, where radiographs showed the mass. Murmur. Receiving furosemide, enalapril, and pimobendan.

## ECHOCARDIOGRAPHIC FINDINGS

2D, M-mode, and Doppler study.

Left atrial size is normal. The mitral valve is normal. Left ventricular dimensions are normal. Left ventricular systolic function is hyperdynamic. The aorta and aortic valve are normal. Right atrial and right ventricular dimensions are normal. The tricuspid valve is normal. The pulmonary artery and pulmonic valve are normal. No pericardial effusion or cardiac masses are seen. A large (~5.13 cm x 4.28 cm) thoracic mass can be seen adjacent to the left heart chambers.

ECG during echo: Sinus arrhythmia

LA - 21.9 mm  
LVIDd - 21.7 mm  
LVIDs - 11.5 mm  
FS - 47%  
RA - 16.3 mm  
LVOT - 1.02 m/s  
RVOT - 1.08 m/s

## ASSESSMENT/RECOMMENDATIONS

Normal echocardiogram

This examination demonstrates no evidence of structural heart disease. As such, no reason for Mia's reported murmur is appreciated in the image set, and it's likely that the murmur is functional/innocent in nature.

No cardiovascular contraindication to general anesthesia is appreciated in this exam, though I do recommend pre-oxygenating Mia prior to induction.

No indication for the continued use of Mia's current cardiac medications is appreciated in this exam.

A recheck echocardiogram is recommended if new physical exam and/or clinical abnormalities suggestive of the presence of structural heart disease develop.



## PATIENT

Mia Caban

## SPECIES

Canine

## BREED

Mixed

## SEX

FS

## AGE

8 y

## WEIGHT

14.6 lb

## INTERPRETED BY

Keith Blass, DVM, MS,  
DACVIM (Cardiology)

## IMAGING PERFORMED BY

Gabriel Ferrer, DVM

## HOSPITAL NAME

Pulse Pet Ultrasound  
Services

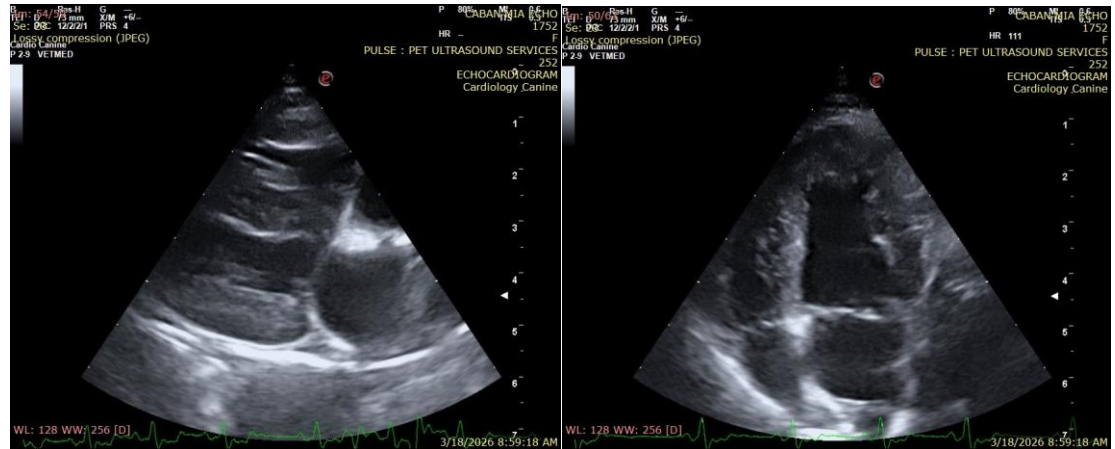
## REFERRING VET

Dr. Trappler

## INVOICE

## DATE

3/18/26



The information and recommendations provided are based on the images presented by the referring veterinarian/sonographer. No evaluation can be communicated regarding pathology that was not visible in the image/video clips provided.

Thank you for this referral. If the clinical or image interpretation does not parallel your findings or if I can be of any further assistance please contact me.

Keith Blass, DVM, MS, DACVIM (Cardiology) [info@SonoPath.com](mailto:info@SonoPath.com)